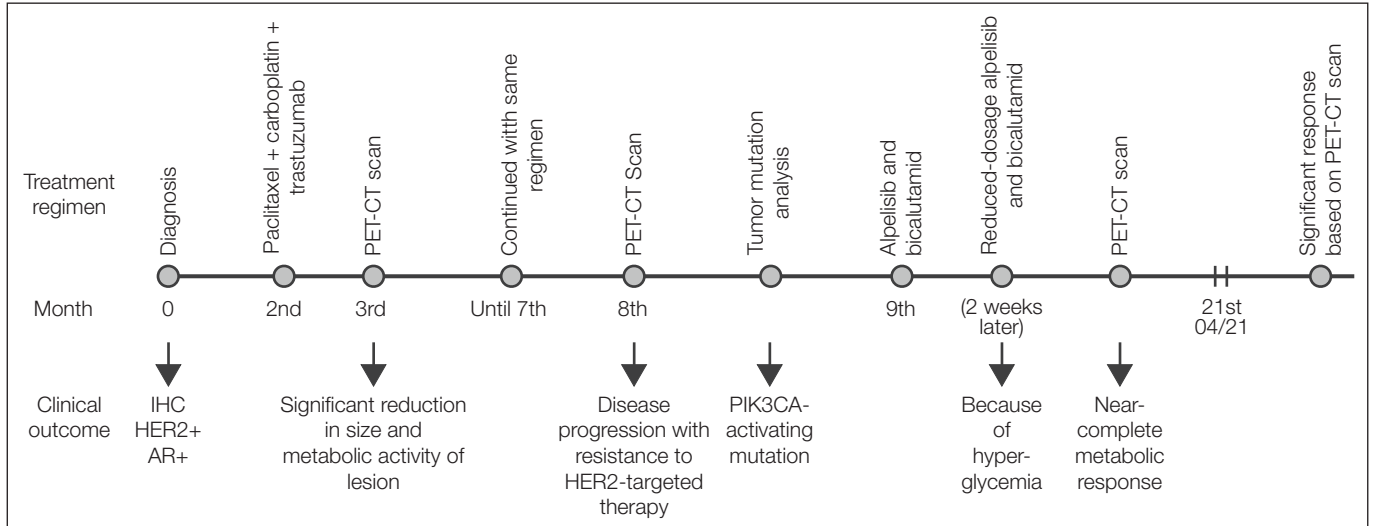


Case Study I

Advanced salivary duct carcinoma, 64-year-old male patient



Result of the recommended therapy

