

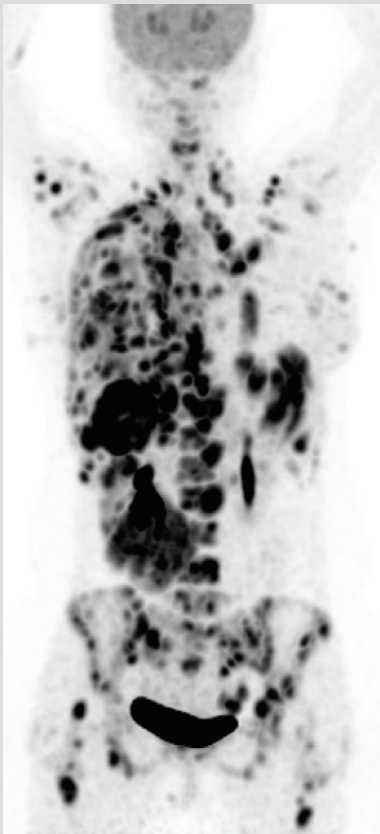
Case Study II

Stage IV Triple negative breast cancer 22 year old female patient

Clinical History	
Aug '16	Diagnosis: TNBC
Aug – Jan '16	Cyclophosphamide + Doxorubicin + Docetaxel
Nov '16	Left Mastectomy
Feb – Mar '17	Radiotherapy
May – Jun '17	Methotrexate + Cyclophosphamide
Jun – Jul '17	Everolimus
Jul '17	PET-CT: Progression

exaota® rationale for therapy selection		
Gene / Pathway / Analysis	Results	Therapeutic Implication
PDGFRA, KIT, KDR	Gain of Copy	Axitinib
Chemosensitivity	Cytotoxicity	Carboplatin Gemcitabine

Benefit from exaota® – recommended therapy

<p>before</p> <p>Cancer had progressed following 5 lines of therapy.</p>		<p>after</p> <p>Administration of exaota: recommended therapy led to regression of cancer.</p>
day 0	day 34	